

51

EXAMINATION PROTOCOL

2016-09419 FISHER, CARRIE F

scl

FOLLOW FORM EXACTLY AS PRINTED
CIRCLE OR CHECK ONE OR THOSE THAT APPLY
REMEMBER THE FORM IS PRINTED ON BOTH SIDES

Page 1 of 2

The body is identified by toe tags. Diagram(s) & form(s) used 20

The body [ ] is clothed and [x] was not clothed

and I [ ] inspected the clothing. [x] did not see the clothing.

The clothing can be described as

[x] Rigor has presumably been altered/abolished as has livor.
[ ] Rigor mortis is present. Livor mortis is

Appears: [ ] Asian [ ] Black [x] Caucasian [ ] Hispanic [ ] Indian
Sex: [ ] Male [x] Female. Appears the stated age of: 60 years

The body weighs approximately 171 pounds, measures approx 61 inches and is
[ ] cachectic.
[ ] mildly/moderately/extremely obese.
[ ] poorly nourished
[ ] thin.
[x] well-built, muscular and fairly well-nourished.
[ ] status post hospitalization. (see diagram)

Embalmed: [x] No [ ] Yes [ ] Decomposed [ ] Mutilated
Irides: [ ] Blue [x] Brown [ ] Grey [ ] Hazel
Sclera: [x] Normal [ ] Icteric Congested with/without Petechial Hemorrhage
Conjunctival Petechial Hemorrhage: [x] No [ ] Yes Facial Petechial Hemorrhage [x] No [ ] Yes
Head Hair: [ ] Black [ ] Blond [ ] Brown [x] Gray [ ] Red [ ] White
[x] Long [ ] Short [ ] Curly [x] Straight [ ] Tightly Curled [ ] Wavy
Balding is: [x] Absent [ ] Present Located: temple/frontal/occipital
Mustache: [x] Absent [ ] Present Beard: [x] Absent [ ] Present
Teeth: [ ] Absent [x] Present Comment:
Dentures: [x] Absent [ ] Present Comment:
Scars: [x] None [x] Present Comment:
(Includes needle track scars)
Wrist scars: [x] None [ ] Present

EXAMINATION PROTOCOL

CASE NUMBER 16-9419

page 2 of 2

Tattoos:  Absent  Present Comment: \_\_\_\_\_

Deformities:  Absent  Present Comment: \_\_\_\_\_

There is no deformity or abnormal mobility of the extremities except for \_\_\_\_\_

Resuscitative marks ~~are~~ are not present over the precordium. The chest has no ~~an~~ a mildly increased anterior-posterior diameter.

The abdomen is

- distended.
- flat.
- not unusual.
- obese.
- scaphoid.

The genitalia are those of an adult

- female.
- male.

Examination of the back & buttocks reveals see diagram

Examination of the skin reveals \_\_\_\_\_

IF A TRAUMA CASE STATE: Injury date: \_\_\_\_\_ Hospital Date(s): 12-23 to 12-31-16

TRAUMA COMMENTS: None

Photographs	<input checked="" type="checkbox"/> Yes <input checked="" type="checkbox"/> No	Fluoroscopy	<input type="checkbox"/> Yes <input checked="" type="checkbox"/> No
X-Rays	<input checked="" type="checkbox"/> Yes <input checked="" type="checkbox"/> No (CT scan)	Cultures	<input type="checkbox"/> Yes <input checked="" type="checkbox"/> No
Toxicology	<input checked="" type="checkbox"/> Yes <input type="checkbox"/> No	Cassettes	<input type="checkbox"/> Yes <input checked="" type="checkbox"/> No
GSR	<input type="checkbox"/> Yes <input checked="" type="checkbox"/> No	Evidence	<input type="checkbox"/> Yes <input checked="" type="checkbox"/> No

Indicate other form number(s) attached 20

**OPINION** (please print)

see attached opinion

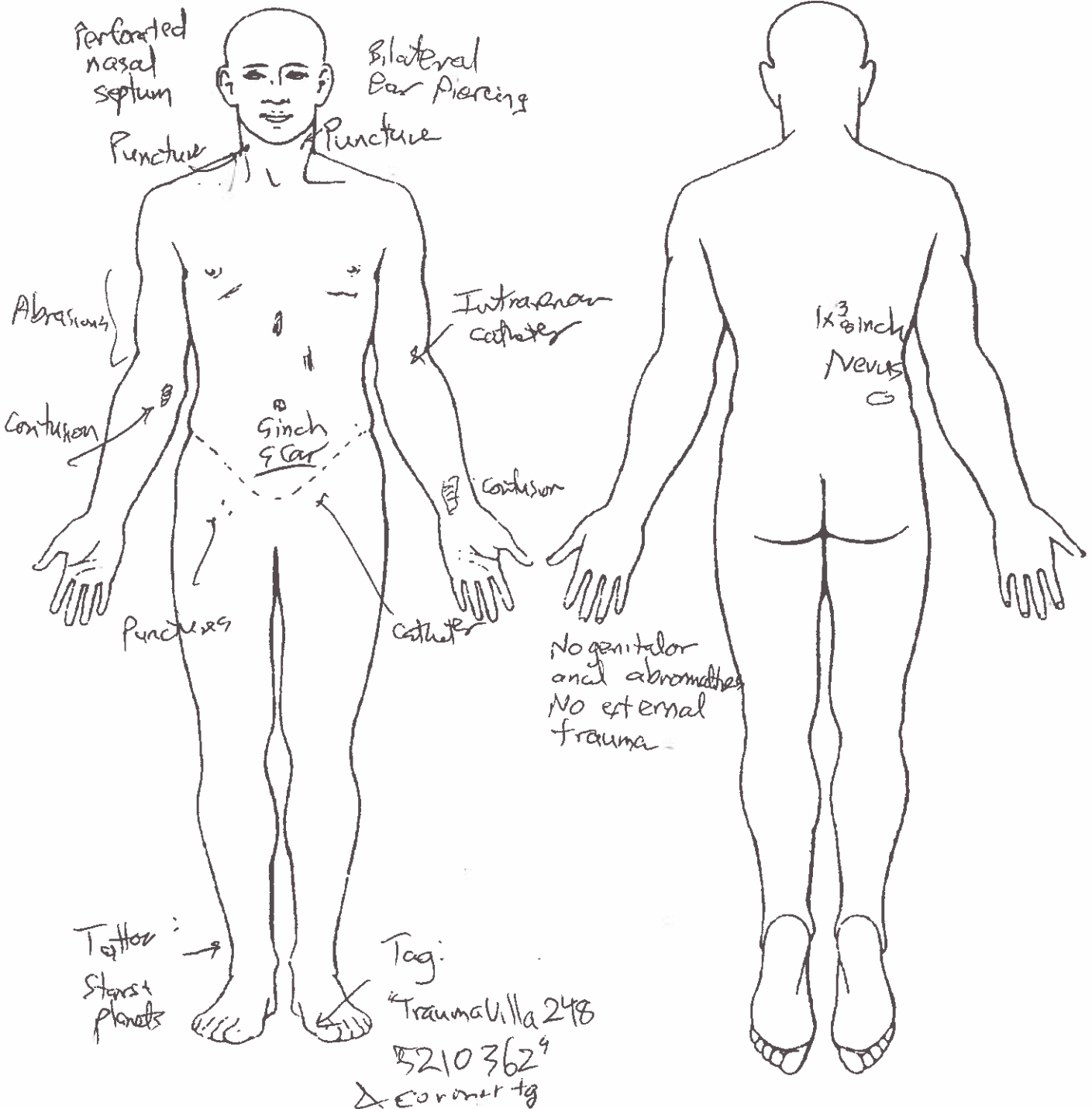
[Signature]  
DEPUTY MEDICAL EXAMINER

Date 12-30-16  
REV. 08/14

20

2016-09419  
FISHER, CARRIE F  
N/A

scl



Date

*John Howard*  
*Deputy Medical Examiner*

1115  
12-30-16 M.D.

**12**

No.

2016-09419

Fisher, Carrie

Page 1

## OPINION:

This decedent was unresponsive following emesis near the end of a long flight on 12-23-16. She had a history of sleep apnea and bipolar disorder, which was under therapy. Cardiopulmonary resuscitation was performed during the flight and while being transported to a local hospital. Urine toxicology on admission to the hospital was positive for cocaine, methadone, ethanol, and opiates. She was pronounced dead on 12-27-16 after a four-day survival.

She was brought to the Coroner's Office on 12-27-16. A CT scan on 12-27 showed skeletal degenerative arthritis and spondylosis, mild diffuse cerebral atrophy, and mild cardiomegaly with sites of coronary artery calcification. An external examination was done on 12-30-16, as the family objected to autopsy.

An extensive toxicology screen was conducted on the hospital serum specimen from the day of admission, and postmortem bile, liver and vitreous (see report). However, limited toxicology specimens were available. Based on the available toxicological information, limited history of present illness, lack of correlating symptoms and medical observation, there are significant limitations in one's ability to interpret the toxicology results and their contribution to cause of death.

Based on the current information, the cause of death is "Sleep apnea and other undetermined factors", other conditions "Atherosclerotic heart disease, drug use", how injury occurred "Multiple drug intake, significance not ascertained", manner of death undetermined.



Christopher Rogers, M.D.  
Acting Chief Medical Examiner-Coroner

5-15-17  
Date



Lakshmanan Sathyavagiswaran, M.D.  
Consultant and Director of Operations

5-15-2017  
Date

CR:LS:mtm  
T: 5/8/17

13

**RADIOLOGY CONSULT  
CT SCAN REPORT****2016-09419  
Fisher, Carrie****REQUEST:**

Sixty-year-old Caucasian woman with history of sleep apnea who had unexpected cardiac arrest and lived 4 days. Please examine CT scan for disease or injury.

**RADIOGRAPHIC IMAGES:**

Whole Body Computed Tomographic (CT) Radiographic Survey.

Screening CT scan examination of the decedent's body were performed, with the body in the supine position, including axial images of the head, neck, torso and major portions of the upper and lower extremities. Coronal and sagittal reformatted images of the head, cervical spine and torso were included. The images were reviewed utilizing bone and soft tissue factors.

Head and Neck: The scalp and superficial soft tissues are unremarkable. There is no visible free intracranial blood. There is mild diffuse cerebral cortical atrophy c/w the decedent's recorded age. There is extensive soft tissue and/or fluid density within paranasal sinuses, middle and inner ear portions of the temporal bones, and mastoid air cells. Extensive metallic dental restoration is present which obscures portions of the face. There are a few intracranial air density collections which appear intravascular. There is extensive severe arthritic change throughout the cervical spine. There are no visible skull or cervical spine fractures. The pre-vertebral soft tissues are normal. Basicervical and spinal alignment are normal.

Torso and Included Extremities: The superficial soft tissues, including the subcutaneous fat, are normal. The lungs are poorly aerated, with extensive opacification c/w post mortem atelectasis. The cardiac structure appears to be mildly enlarged. There are sites of mild coronary artery calcification. Numerous air bubbles are seen within the heart and aorta (both intrathoracic and intraabdominal). Intravascular air density is present within several abdominal organs. No free air is seen within the chest or abdomen. Moderate to severe degenerative changes are seen throughout the thoracic and lumbar spine, as well as the pelvis. Skeletal structures are otherwise normal. Specifically there is no visible skeletal fracture or evidence of other skeletal trauma. Iatrogenic left inguinal intravenous catheter is present. No other foreign body is visible. There is faint increased density within the right renal pelvis which, in the absence of intravenous contrast, could represent early formation of a renal calculus.

**IMPRESSION:**

The peripheral soft tissues and the skeletal structures are normal except for extensive skeletal degenerative arthritis and spondylosis. There is no evidence of significant congenital or developmental skeletal anomaly. There is no CT radiographic evidence of intracranial bleeding. There is mild diffuse cerebral cortical atrophy, probably age related, and mild cardiomegaly with sites of mild coronary artery calcification. There is extensive soft tissue and/or fluid density within paranasal sinuses, middle and inner ear portions of the temporal bones, and mastoid air cells, etiology indeterminate. There is intravascular air density within head, chest and abdomen, also etiology indeterminate. There is no visible tumor or other mass.



Donald C. Boger, M.D.  
Radiology Consultant

1/24/17  
Date

**13****FORENSIC CONSULTANT'S REPORT**

No.

2016-09419

Fisher, Carrie

Page 2**2) Send out samples for amphetamines**

Bile: Positive for methylene-dioxy-amphetamine (MDA) 18ng/mL (GC/MS)

Liver: Negative for all amphetamine derivatives (GC/MS)

**3) Bile fluid**

Positive for morphine 0.82 mcg/mL

Negative for 6-MAM, codeine, hydrocodone, hydromorphone

Negative for oxycodone, oxymorphone

GC/MS

**4) Liver**

Positive for diphenhydramine 1.4 mcg/g

Positive for fluoxetine 18 mcg/g /norfluoxetine 7.4 mcg/g

Positive for meperidine 0.74 mcg/g /normeperidine negative

Positive for methadone 2.0 mcg/g

Positive for morphine 0.09 mcg/mL

Negative for normeperidine, codeine, hydrocodone, hydromorphone

Negative for oxycodone, oxymorphone

GC/MS

**5) Vitreous sample**

Positive for 6-monoacetyl morphine (6-MAM)

Positive for morphine 0.12 mcg/mL

Negative for codeine, hydrocodone, hydromorphone

Negative for oxycodone, oxymorphone

GC/MS

A full body CT was also performed, which revealed degenerative arthritic findings, mild cardiomegaly with age-related calcifications, and no evidence of bleeds/masses.

With regard to the substance detected in blood and other tissues, I will go through them systematically here:

**13****FORENSIC CONSULTANT'S REPORT**

No.

2016-09419

Fisher, Carrie

Page 3

**1) Cocaine:** The presence of cocaine was detected initially on urine drug screen via ELISA immunoassay on the first day of hospitalization. ELISA does not confirm the presence of cocaine parent compound necessarily. Subsequent testing of serum hospital blood sample showed confirmation of benzoylecgonine, which is a metabolite of cocaine. The quantity of blood was not sufficient enough to confirm the presence of cocaine parent compound. The reason that this is relevant is that a positive confirmation of the parent compound would suggest exposure within approximately 24 hours of the sample that was obtained. Confirmation of only benzoylecgonine tells us that the exposure to cocaine took place sometime approximately in the last 72 hours of the sample that was obtained. This means that the cocaine was administered possibly as early as 12-20-16, and there is no way to estimate the dose or the time of exposure based on the current information about benzoylecgonine in this case. One factor that supports the hypothesis of a more remote exposure is the negative result for cocaethylene. Cocaethylene is a substance that the liver synthesizes, when cocaine and ethanol are both present in the body at the same time. We have toxicological evidence that ethanol was present on 12-23-16. Therefore, the lack of cocaethylene detected would suggest that the cocaine exposure likely took place before the ethanol exposure took place. This is a relatively broad estimation based on very limited available data, but it would qualitatively reduce the potential contribution of cocaine to the cause of death. At this time, the significance of cocaine cannot be established in this case.

**2) Opiates/opioids, including methadone, meperidine, morphine, and 6-MAM:**

The presence of 6-MAM in the vitreous sample indicates that exposure to heroin took place. This compound (6-MAM) has a short half-life at approximately 2 hours. The detection of 6-MAM in the vitreous sample with the absence of 6-MAM in other tissue samples suggests that there was an exposure to heroin, but that the dose and time of exposure cannot be pinpointed. Therefore we cannot establish the significance of heroin regarding the cause of death in this case. The other opiate/opioid substances detected included morphine, methadone, and meperidine. The morphine may simply be present as a metabolite of heroin, or it may have been administered separately, though this cannot be confirmed based on the available information. All of the above substances are capable of suppressing breathing/respiratory drive. However, the available information is insufficient to establish the significance of opiates and opioids in this case regarding cause of death.

**3) Methylene dioxy methamphetamine (MDA):**

MDA is the chief metabolite of MDMA. This was detected only on the bile sample, with a presumptive positive by ELISA on the serum blood sample. This result suggests that there was a remote exposure to MDMA, but it is not possible to pinpoint the exposure time or the dose. Therefore, the significance of MDA cannot be established regarding cause of death in this case.

**13****FORENSIC CONSULTANT'S REPORT**

No.

2016-09419

Fisher, Carrie

Page 4**4) Diphenhydramine and fluoxetine:**

Fluoxetine was detected in serum blood from the 12-23-16 sample. The level would not suggest a toxic amount of fluoxetine. The diphenhydramine is also present in a very low concentration. The significance of these substances is likely very low regarding the cause of death in this case.

Overall, this case contains limited available toxicological information. Drugs of abuse such as cocaine, heroin, and amphetamine derivatives are very difficult to interpret based on quantitative levels in tissue or blood postmortem. Also, antemortem levels of these drugs are also difficult to evaluate, with a lack of correlating symptoms and medical observation. We have a very limited history of presenting illness as well, which further limits the interpretation of the toxicological data.

Ms. Fisher suffered what appeared to be a cardiac arrest on the airplane, accompanied by vomiting and with a history of sleep apnea. Based on the available toxicological information, we cannot establish the significance of the multiple substances that were detected in Ms. Fisher's blood and tissue, with regard to the cause of death.

This assessment is based on my review of the available records at the Department of Coroner on 3-15-17.



CYRUS RANGAN, MD FAAP, FACMT  
CONSULTANT IN MEDICAL TOXICOLOGY

5-15-2017

DATE

CR:mtm  
T: 5/08/17



**13****FORENSIC CONSULTANT'S REPORT**

No.

2016-09419

Fisher, Carrie

**Medical Toxicology Consultation (3-15-17):**

I was requested by Dr. Lakshmanan Sathyavagiswaran to review and comment upon the toxicology lab results for the case of Carrie Fisher #2016-09419. In brief summary, Ms. Fisher was on an airplane as a passenger on 12-23-16. She was reportedly sleeping in a sitting position next to her personal assistant. She had a past medical history of sleep apnea and bipolar disorder. The records I reviewed indicate that Ms. Fisher routinely had apneic episodes during sleep. Approximately 15 minutes before landing, she had an episode of vomiting and was subsequently unarousable. CPR was initiated by other passengers. Upon landing, paramedics administered sodium bicarbonates and epinephrine. A pulse was observed in the 70's, and she remained unarousable. She was transported to Ronald Reagan/UCLA Hospital. There, she underwent a urine screen for drugs of abuse which was positive for cocaine, methadone, ethanol, and opiates, and negative for amphetamines, barbiturates, benzodiazepines, cannabinoids, and oxycodone. Testing method was ELISA immunoassay. EKG revealed S-T abnormalities, but it was not recorded whether these were new changes or old findings. She had a BP 130/60 on arrival, with dilated pupils. Ms. Fisher underwent therapeutic hypothermia and hemodialysis during her hospitalization. On 12-27-16, Ms. Fisher had cardiac arrest in the AM, and was pronounced after approximately 90 minute of ACLS. Past medical history included sleep apnea and also bipolar disorder, for which she was reportedly on Abilify (aripiprazole), Prozac (fluoxetine), and Lamictal (lamotrigine). Doses and intervals were not available to me at the time of this consultation.

Additional toxicological testing was obtained by the Medical Examiner/Department of Coroner. Findings included the following:

**1) Hospital serum from 12-23-16 sample of blood**

Positive for benzoylecgonine  
Negative for cocaethylene  
QNS for cocaine present compound

GC/MS

Positive for cocaine and metabolite  
Positive for methadone  
Positive for methamphetamine/MDMA  
Positive for opiates  
Negative for PCP, codeine, oxycodone, hydrocodone

ELISA Presumptive  
positive

15

AUTOPSY CLASS:  A  B  C  Examination Only D  
 FAMILY OBJECTION TO AUTOPSY  
Date: 12-30-16 Time: 1045 Dr. Rogers/Lakshmanan  
FINAL ON: 6-6-17 By: Rogers/Lakshmanan

APPROXIMATE INTERVAL BETWEEN ONSET AND DEATH

16-09419  
SHER. CARRIE F  
scl

DEATH WAS CAUSED BY: (Enter only one cause per line for A, B, C, and D)

IMMEDIATE CAUSE: sleep apnea and other undetermined  
(A) Cardiac arrest/deferred factors

unk

Age: 60 Gender: Male / Female

PRIOR EXAMINATION REVIEW BY DME

DUE TO, OR AS A CONSEQUENCE OF:

(B)

BODY TAG CR/LS  CLOTHING  
 X-RAY (No. \_\_\_\_\_)  FLUORO  
 SPECIAL PROCESSING TAG  MED. RECORDS  
 AT SCENE PHOTOS (No. \_\_\_\_\_)

DUE TO, OR AS A CONSEQUENCE OF:

(C)

CASE CIRCUMSTANCES

DUE TO, OR AS A CONSEQUENCE OF:

(D)

EMBALMED  
 DECOMPOSED  
 > 24 HRS IN HOSPITAL  
 OTHER: \_\_\_\_\_ (Reason)

OTHER CONDITIONS CONTRIBUTING BUT NOT RELATED TO THE IMMEDIATE CAUSE OF DEATH:

Atherosclerotic heart disease drug use

TYPING SPECIMEN

NATURAL  SUICIDE  HOMICIDE  
 ACCIDENT  COULD NOT BE DETERMINED

TYPING SPECIMEN TAKEN BY: CR

SOURCE: Jugular

If other than natural causes, HOW DID INJURY OCCUR?

Multiple drug intake, significance not established

TOXICOLOGY SPECIMEN

COLLECTED BY: CR  
 HEART BLOOD  STOMACH CONTENTS  
 FEMORAL BLOOD  VITREOUS  
TECHNIQUE: Ext  
 Jugular BLOOD  SPLEEN  
 BLOOD  KIDNEY  
 BILE   
 LIVER   
 URINE

WAS OPERATION PERFORMED FOR ANY CONDITION STATED ABOVE:  YES  NO

TYPE OF SURGERY: \_\_\_\_\_ DATE: \_\_\_\_\_

ORGAN PROCUREMENT  TECHNICIAN: C. de la Torre / M. Fernandez

PREGNANCY IN LAST YEAR  YES  NO  UNK  NOT APPLICABLE

WITNESS TO AUTOPSY  EVIDENCE RECOVERED AT AUTOPSY  
Item Description: Present and assisted:  
FA Welsh  
Brian Elias

URINE GLUCOSE DIPSTICK RESULT: 4+ 3+ 2+ 1+ 0  
TOX SPECIMEN RECONCILIATION BY: \_\_\_\_\_

HISTOLOGY

Regular (No. \_\_\_\_\_)  Oversize (No. \_\_\_\_\_)  
Histopath Cut:  Autopsy  Lab

TOXICOLOGY REQUESTS

FORM 3A:  YES  NO  
 NO TOXICOLOGY REQUESTED  
SCREEN  C  H  T  S  D  
 ALCOHOL ONLY  
 CARBON MONOXIDE  
 OTHER (Specify drug and tissue)  
opiate

REQUESTED MATERIAL ON PENDING CASES

POLICE REPORT  MED HISTORY  
 TOX FOR COD  HISTOLOGY  
 TOX FOR R/O  INVESTIGATIONS  
 MICROBIOLOGY  EYE PATH. CONS.  
 RADIOLOGY CONS.  
 CONSULT ON: \_\_\_\_\_  
 BRAIN SUBMITTED  
 NEURO CONSULT  DME TO CUT  
 CRIMINALISTICS  
 GSR  SEXUAL ASSAULT  OTHER

RESIDENT

DME

Johnno -  
Singer -  
Christy -  
Chief FM.



# COUNTY OF LOS ANGELES

## DEPARTMENT OF MEDICAL EXAMINER-CORONER

1104 N. MISSION RD, LOS ANGELES, CALIFORNIA 90033



**Christopher B. Rogers, M.D.**  
Acting Chief Medical Examiner-Coroner

Rogers, Christopher M.D.  
Acting Chief Medical Examiner-Coroner  
1104 North Mission Road  
Los Angeles, CA 90033

March 13, 2017

### **ADDENDUM: 2016-09419 Toxicology Report**

Decedent: Fisher, Carrie Francis

Hospital Serum was analyzed by the following services: ELISA-Immunoassay, Cocaine-GC/MS, and Opiates-GC/MS. Aliquots were sampled from two (2) different vials of Hospital Serum; the collection information is as follows:

1. The ELISA-Immunoassay analysis was performed on an aliquot from a light blue top vial with a printed date of 12-23 and a printed time of 1332 hours.
2. The Cocaine-GC/MS and Opiates-GC/MS analyses were performed on aliquots from a light blue top vial with a printed date of 12-23-16 and a printed time of 1332 hours.

This addendum was prepared by:

Caitlin Miller, M.S., D-ABFT-FT  
Supervising Criminalist, Toxicology  
(323) 343-0659, cmiller@coroner.lacounty.gov

#### **Accreditations:**

*National Association of Medical Examiners (Provisional)*  
*California Medical Association-Continuing Medical Education*  
*Accreditation Council for Graduate Medical Education*

*American Society of Crime Laboratory Directors/LAB-International*  
*Peace Officer Standards and Training Certified*



Department of Medical Examiner-Coroner, County of Los Angeles

# FORENSIC SCIENCE LABORATORIES

1104 North Mission Road Los Angeles, CA 90033

## Laboratory Analysis Summary Report



Rogers, Christopher M.D.

Deputy Medical Examiner  
1104 North Mission Road  
Los Angeles, CA 90033

PendingTox

The following results have been technically and administratively reviewed and are the opinions and conclusions of the Analyst:

**Coroner Case Number:** 2016-09419 **Decedent:** FISHER, CARRIE FRANCES

<u>SPECIMEN</u>	<u>SERVICE</u>	<u>DRUG</u>	<u>RESULT</u>	<u>ANALYST</u>
<b>Bile</b>				
	Opiates-GC/MS	6-Monoacetylmorphine	ND	E. Fu
	Opiates-GC/MS	Codeine, Free	ND	E. Fu
	Opiates-GC/MS	Hydrocodone, Free	ND	E. Fu
	Opiates-GC/MS	Hydromorphone, Free	ND	E. Fu
	Opiates-GC/MS	Morphine, Free	0.82 ug/mL	E. Fu
	Opiates-GC/MS	Oxycodone, Free	ND	E. Fu
	Opiates-GC/MS	Oxymorphone, Free	ND	E. Fu
	Outside Test	Sympathomimetic Amines	Done	NMS Labs, Inc.
<b>Liver</b>				
	Bases-GC/NPD &/or MS	Diphenhydramine	1.4 ug/g	B. Ciullo
	Bases-GC/NPD &/or MS	Fluoxetine	18 ug/g	B. Ciullo
	Bases-GC/NPD &/or MS	Meperidine	0.74 ug/g	B. Ciullo
	Bases-GC/NPD &/or MS	Methadone	2.0 ug/g	B. Ciullo
	Bases-GC/NPD &/or MS	Norfluoxetine	7.4 ug/g	B. Ciullo
	Bases-GC/NPD &/or MS	Normeperidine	ND	B. Ciullo
	Opiates-GC/MS	Codeine, Free	ND	E. Fu
	Opiates-GC/MS	Hydrocodone, Free	ND	E. Fu
	Opiates-GC/MS	Hydromorphone, Free	ND	E. Fu
	Opiates-GC/MS	Morphine, Free	0.09 ug/mL	E. Fu
	Opiates-GC/MS	Oxycodone, Free	ND	E. Fu
	Opiates-GC/MS	Oxymorphone, Free	ND	E. Fu
	Outside Test	Sympathomimetic Amines	Done	NMS Labs, Inc.
<b>Serum, Hospital</b>				
	Cocaine-GC/MS	Benzoylcegonine	10 ug/mL	S. DeQuintana
	Cocaine-GC/MS	Cocaethylene	ND	S. DeQuintana
	Cocaine-GC/MS	Cocaine	* QNS	S. DeQuintana
	ELISA-Immunoassay	Cocaine and Metabolites	PP	J. Gadoway
	ELISA-Immunoassay	Fentanyl	ND	J. Gadoway

**Coroner Case Number: 2016-09419 Decedent: FISHER, CARRIE FRANCES**

<u>SPECIMEN</u>	<u>SERVICE</u>	<u>DRUG</u>	<u>RESULT</u>	<u>ANALYST</u>
	ELISA-Immunoassay	Methadone	PP	J. Gadway
	ELISA-Immunoassay	Methamphetamine & MDMA	PP	J. Gadway
	ELISA-Immunoassay	Opiates: Codeine & Morphine	PP	J. Gadway
	ELISA-Immunoassay	Opiates: Hydrocodone & Hydromorphone	PP	J. Gadway
	ELISA-Immunoassay	Phencyclidine	ND	J. Gadway
	Opiates-GC/MS	Codeine, Free	ND	E. Fu
	Opiates-GC/MS	Hydrocodone, Free	ND	E. Fu
	Opiates-GC/MS	Hydromorphone, Free	ND	E. Fu
	Opiates-GC/MS	Morphine, Free	* QNS	E. Fu
	Opiates-GC/MS	Oxycodone, Free	ND	E. Fu
	Opiates-GC/MS	Oxymorphone, Free	ND	E. Fu
<b>Vitreous</b>				
	Opiates-GC/MS	6-Monoacetylmorphine	Present	E. Fu
	Opiates-GC/MS	Codeine, Free	ND	E. Fu
	Opiates-GC/MS	Hydrocodone, Free	ND	E. Fu
	Opiates-GC/MS	Hydromorphone, Free	ND	E. Fu
	Opiates-GC/MS	Morphine, Free	0.12 ug/mL	E. Fu
	Opiates-GC/MS	Oxycodone, Free	ND	E. Fu
	Opiates-GC/MS	Oxymorphone, Free	ND	E. Fu

NOTE: \* = Volume of specimen not sufficient for confirmation/quantitation.

<b>Legend:</b>		mg/dL	Milligram per Deciliter	PP	Presumptive Positive
g	Grams	mg/L	Milligram per Liter	QNS	Quantity Not Sufficient
g%	Gram Percent	ND	Not Detected	ug	Micrograms
Inc.	Inconclusive	ng/g	Nanograms per Gram	ug/g	Micrograms per Gram
mg	Milligrams	ng/mL	Nanograms per Milliliter	ug/mL	Microgram per Milliliter

In accordance with the Department's Evidence Retention Policy, the blood specimen(s) will be retained for one-year and all other specimens for six-months from Autopsy.

Administratively reviewed by:  Caitlin Miller, M.S., D-ABFT-FT  
 Supervising Criminalist TOXICOLOGY  
 (323) 343-0659 cmiller@coroner.lacounty.gov



NMS Labs

CONFIDENTIAL

3701 Welsh Road, PO Box 433A, Willow Grove, PA 19090-0437
Phone: (215) 657-4900 Fax: (215) 657-2972
e-mail: nms@nmslabs.com
Robert A. Middleberg, PhD, F-ABFT, DABCC-TC, Laboratory Director

Toxicology Report

Report Issued 01/13/2017 14:00

10139

Los Angeles County Coroner Medical Examiner
Attn: Mark Schuchardt
1104 N. Mission Road
Los Angeles, CA 90033

Patient Name NP

Patient ID 2016-09419

Chain 17003338

Age Not Given DOB Not Given

Gender Not Given

Workorder 17003338

Received 01/05/2017 16:13

Chain of custody documentation has been maintained for the analyses performed by NMS Labs.

Unless alternate arrangements are made by you, the remainder of the submitted specimens will be discarded six (6) weeks from the date of this report; and generated data will be discarded five (5) years from the date the analyses were performed.

Sample ID 17003338-001
Matrix Fluid
Patient Name NP
Patient ID 2016-09419
Container Type Blue Vial

Collect Dt/Tm 01/04/2014 09:00
Source Bile

Approx Vol/Weight 5 mL

Receipt Notes None Entered

Table with 5 columns: Analysis and Comments, Result, Units, Reporting Limit, Notes. Contains data for 8600FL Amphetamines Panel, Fluid analysis.

Results for sample 17003338-001 are continued on next page

LA Medical Examiner-Coroner Forensic Laboratory
Ok to Release 1/18/17

O. Pleitez
Page 1 of 5

Handwritten signature



NMS Labs

CONFIDENTIAL

3701 Welsh Road, PO Box 433A, Willow Grove, PA 19090-0437
Phone: (215) 657-4900 Fax: (215) 657-2972
e-mail: nms@nmslabs.com
Robert A. Middleberg, PhD, F-ABFT, DABCC-TC, Laboratory Director

Sample ID 17003338-001
Matrix Fluid
Patient Name NP
Patient ID 2016-09419

Collect Dt/Tm 01/04/2014 09:00
Source Bile

Table with 5 columns: Analysis and Comments, Result, Units, Reporting Limit, Notes. Rows include Methamphetamine, MDA, MDMA, and MDEA with their respective results and reporting limits.

Handwritten signature



**NMS Labs**

3701 Welsh Road, PO Box 433A, Willow Grove, PA 19090-0437  
Phone: (215) 657-4900 Fax: (215) 657-2972  
e-mail: nms@nmslabs.com  
Robert A. Middleberg, PhD, F-ABFT, DABCC-TC, Laboratory Director

**CONFIDENTIAL**

**Sample ID** 17003338-002  
**Matrix** Fluid  
**Patient Name** NP  
**Patient ID** 2016-09419  
**Container Type** Blue Vial

**Collect Dt/Tm** 01/04/2017 09:00  
**Source** Tissue Homogenate  
*Liver (Y<sub>2</sub>)*  
**Approx Vol/Weight** 4.5 mL

**Receipt Notes** None Entered

Fluid specimen required homogenization: 17003338-002

No testing performed on this sample.

A handwritten signature in black ink, appearing to be 'OP'.





NMS Labs

CONFIDENTIAL

3701 Welsh Road, PO Box 433A, Willow Grove, PA 19090-0437
Phone: (215) 657-4900 Fax: (215) 657-2972
e-mail: nms@nmslabs.com
Robert A. Middleberg, PhD, F-ABFT, DABCC-TC, Laboratory Director

Sample ID 17003338-003
Matrix Fluid
Patient Name NP
Patient ID 2016-09419
Container Type Homogenate Container

Collect Dt/Tm 01/04/2017 09:00
Source Tissue Homogenate
Liver (1/2)
Approx Vol/Weight Not Given

Receipt Notes None Entered

NMS Labs generated homogenized Fluid sample: 17003338-003

Table with 5 columns: Analysis and Comments, Result, Units, Reporting Limit, Notes. Contains results for 8600FL Amphetamines Panel, Fluid, listing various substances like Ephedrine, Pseudoephedrine, etc., all as 'None Detected'.

LA Medical Examiner-Coroner Forensic Laboratory

Ok to Release

1/18/17

O. Pleitez
Page 4 of 5

Handwritten signature



**NMS Labs**

**CONFIDENTIAL**

3701 Welsh Road, PO Box 433A, Willow Grove, PA 19090-0437  
Phone: (215) 657-4900 Fax: (215) 657-2972  
e-mail: nms@nmslabs.com  
Robert A. Middleberg, PhD, F-ABFT, DABCC-TC, Laboratory Director

2016-09419

Workorder 17003338 was electronically  
signed on 01/13/2017 13:20 by:

A handwritten signature in black ink, appearing to read "E. Barbieri", written over a horizontal line.

Edward J. Barbieri, Ph.D.  
Forensic Toxicologist

Handwritten initials "OP" in black ink, consisting of a stylized 'O' and 'P'.

1	APPARENT MODE <b>ACCIDENT/ NATURAL</b>	CASE NO 2016-09419
	SPECIAL CIRCUMSTANCES Media Interest	CRYPT SEC1

LAST, FIRST MIDDLE <b>FISHER, CARRIE FRANCES</b>	AKA	#
---	-----	---

ADDRESS 27200 TOURNEY RD.	CITY VALENCIA	STATE CA	ZIP 91355
------------------------------	------------------	-------------	--------------

SEX FEMALE	RACE APPEARS CAUCASIAN	DOB 10/21/1956	AGE 60	HGT 61 in.	WGT 171 lbs	EYES BROWN	HAIR GRAY	TEETH INCOMPLETE	FACIAL HAIR NONE	ID VIEW Yes	CONDITION FAIR
---------------	---------------------------	-------------------	-----------	---------------	----------------	---------------	--------------	---------------------	---------------------	----------------	-------------------

MARK TYPE TATTOO	MARK LOCATION RIGHT ANKLE	MARK DESCRIPTION MOON & STARS
---------------------	------------------------------	----------------------------------

SSN	DL ID	STATE	PENDING BY
-----	-------	-------	------------

ID METHOD BODY VIEWED AT HOSPITAL
--------------------------------------

LA #	MAIN #	CII #	FBI #	MILITARY #	POB
------	--------	-------	-------	------------	-----

IDENTIFIED BY NAME (PRINT)	RELATIONSHIP	PHONE	DATE	TIME
	DAUGHTER		12/27/2016	

PLACE OF DEATH / PLACE FOUND HOSPITAL RONALD REAGAN UCLA MEDICAL CTR	ADDRESS OR LOCATION 757 WESTWOOD BLVD.	CITY WESTWOOD	ZIP 90095
--	---	------------------	--------------

PLACE OF INJURY	AT WORK No	DATE	TIME	LOCATION OR ADDRESS	ZIP
-----------------	---------------	------	------	---------------------	-----

DOD 12/27/2016	TIME 08:55	FOUND OR PRONOUNCED BY DR. STERN-NEZER
-------------------	---------------	---

OTHER AGENCY INV. OFFICER LAPD ROBBERY HOMICIDE DIVISION - GABLE #3	PHONE (213) 486-6890	REPORT NO. 161227001969	NOTIFIED BY	NO
--	-------------------------	----------------------------	-------------	----

TRANSPORTED BY RUDY MOLANO	TO LOS ANGELES FSC	DATE 12/27/2016	TIME 14:45
-------------------------------	-----------------------	--------------------	---------------

FINGERPRINTS? Yes	CLOTHING No	PARPT No	MORTUARY PIERCE BRO WESTWOOD VILLAGE
MED. EV No	INVEST PHOTO # 25	SEAL TYPE	HOSP RPT Yes
PHYS EV No	EVIDENCE LOG No	PROPERTY? No	HOSP CHART Yes
SUICIDE NOTE No	GSR NO	RCPT. NO. 292234	PF NO 5210362

SYNOPSIS  
CASE ON SECURITY HOLD. SEE CASE NOTES AND INVESTIGATOR'S REPORT/FORM 3 FOR MORE INFORMATION.

VANANDA CHOLAKIAN 604323		INVESTIGATOR	DATE 12/27/2016	REVIEWED BY 	DATE 6/15/17
-----------------------------	---	--------------	--------------------	--	-----------------

FORM #3 NARRATIVE TO FOLLOW?



County of Los Angeles, Department of Coroner  
Investigator's Narrative



Case Number: 2016-09419

Decedent: FISHER, CARRIE FRANCES

**Information Sources:**

- 1) UCLA Ronald Reagan Medical Center Medical Record 757 Westwood Plaza, Los Angeles CA 90095. Including:
  - a. Los Angeles Fire Department Prehospital Care Report Summary Call #0623.

**Investigation:**

On 12/27/2016 at 1122 hours Nurse Supervisor Debra Rothhaar reported this apparent natural versus accidental drug-related death to the Los Angeles County Department of Medical Examiner - Coroner. It was reported that the decedent went into cardiac arrest on a flight from London to Los Angeles on 12/23/2016 and was transported to UCLA Ronald Reagan Medical Center where she remained inpatient until death was pronounced. Her full medical history was not reported due to the medical chart under an alias name not being merged yet, but a history of drug abuse was reported. On 12/27/2016 at 1050 hours I was assigned this field case by Lieutenant E. Fleak. I responded to UCLA Ronald Reagan Medical Center and arrived at 1140 hours. Assistant Chief E. Winter had also just arrived at the hospital. I met with Nursing Supervisor D. Rothbaar and Head of Security, Mr. V. Goodwin. Los Angeles Police Department West Los Angeles Officers Rocida and Sawyer responded to the hospital and obtained information for a death investigation report. I obtained medical records from Nursing Supervisor Rothbaar before conducting my body examination. Investigator R. Molano obtained admission blood samples from the UCLA Medical Center laboratory. I cleared UCLA Medical Center at 1346 hours. Captain J. Kades and Investigator R. Molano transported the decedent to the Forensic Science Center. On 12/27/2016 at 1345 hours Lieutenant E. Fleak emailed a request for medical records to UCLA Medical Center (ksalveson@mednet.ucla.edu). I was not able to interview informants to obtain past medical history information prior to my report completion.

**Location:**

Injury: Unknown.

Death: UCLA Ronald Reagan Medical Center. 757 Westwood Plaza, Los Angeles CA 90095.

**Informant/Witness Statements:**

According to the Los Angeles Fire Department Prehospital Care Report Summary on 12/23/2016 at 1214 hours LAFD Rescue Ambulance 51 was dispatched to "7S LAX", Los Angeles International Airport, and made contact with the decedent at 1224 hours. The decedent was reportedly sleeping during the flight when approximately 15-20 minutes prior to landing she started to vomit and immediately became unresponsive. An RN began CPR immediately and applied an AED which advised no shock. Paramedics arrived and discovered the decedent supine in the aircraft and in aystole with CPR in progress. Her Glasgow coma score was evaluated to be 1-1-1 (3). CPR was continued, bilateral intravenous lines were placed, and she was intubated. There was a return of spontaneous circulation at 1242 hours. Her blood pressure fluctuated during transport but her pulse remained at approximately 75-80. She arrived at UCLA Ronald Reagan emergency department at 1317 hours. Her past medical history was documented as "Psychiatric Problems".

According to the Ronald Reagan UCLA Medical Center medical records, the decedent arrived to the emergency department by ambulance on 12/23/2016 at 1247 hours. An EKG showed no evidence for acute myocardial infarction and an ECHO showed grossly normal ejection fraction and no obvious wall motion abnormality. A chest CT scan showed: multiple bilateral anterior rib fractures and buckle deformities; opacities in the lungs likely reflecting sequelae of aspiration pneumonia; and bibasilar opacities likely reflecting atelectasis. She was admitted with diagnosis of metabolic and respiratory acidosis, most likely related to aspiration versus drug overdose, and underwent dialysis. Urine toxicology collected on 12/23/2016 at 1417 hours was positive for



County of Los Angeles, Department of Coroner  
Investigator's Narrative



Case Number: 2016-09419

Decedent: FISHER, CARRIE FRANCES

cocaine, methadone, opiates, and ethanol. A CT of the head on 12/23 showed no significant edema and a repeat scan on 12/24 was stable. She remained in the ICU with electrolyte abnormalities and acidosis. There was a suspected diagnosis of anoxic brain injury due to lack of circulation and an MRI was planned for 12/27. On 12/27/2016 she went into cardiac arrest around 0721 hours. Despite all resuscitative efforts, death was pronounced inpatient at 0855 hours by Dr. Sara Stern-Nezer. Her past medical history was documented as polysubstance abuse, bipolar disorder, severe sleep apnea, and recurrent pneumonias. She used Abilify, Prozac, and Lamictal, which were prescribed by a medical doctor. She also used oxycodone which was not prescribed. She was reportedly with her personal assistant flying from London back home to Los Angeles. Her personal assistant reported that the decedent was last awake and normal at the beginning of the flight. Throughout the flight she had multiple apneic episodes, which was her baseline, and near the end of the ten hour flight she was not able to be aroused. A few minutes later the decedent vomited profusely then slumped over. It was not bloody or bilious vomit.

**Scene Description:**

Coroner personnel did not visit the scene.

**Evidence:**

I did not collect evidence for this case.

**Body Examination:**

The body examination was conducted at Ronald Reagan UCLA Medical Center in Room #B540. The decedent was observed supine on a steel table wrapped in a sheet and body bag. An identification tag attached to the outside of the bag, an identification tag attached to the left foot, and identification bands around both wrists were labeled as TRAUMA, VILLA248 and MRN: 5210362. The decedent was an adult Caucasian female with shoulder length gray hair, brown eyes, and teeth which appeared to be dental implants. The sclera appeared yellow. Gauze was taped to the bilateral neck and right groin. Intravenous lines were taped to the left groin and left antecubital area. The wrists and ankles were secured together with thin string. There was a tattoo of a moon and stars on the right lateral ankle. There was red discoloration across the body especially centered at the chest and abdomen. Rigor mortis observed at 1250 hours was absent. At 1255 hours livor mortis was observed on the posterior body and blanched with fingertip pressure.

**Identification:**

On 12/27/2016 the decedent was visually identified as Carrie Frances Fisher (DOB 10/21/1956) at the hospital by her daughter, \_\_\_\_\_ as documented on the Form 5. I confirmed this with California Driver License #N5627814 photograph comparison.

**Next of Kin Notification:**

On 12/27/2016 the decedent's daughter and legal next of kin \_\_\_\_\_ was notified of the death by hospital personnel.

**Tissue Donation:**

Family members did not consent to tissue donation by the time of report completion.

**Autopsy Notification:**

There is no request for autopsy notification.



County of Los Angeles, Department of Coroner  
Investigator's Narrative



Case Number: 2016-09419

Decedent: FISHER, CARRIE FRANCES

---

A handwritten signature in black ink, appearing to read "A. Cholakians", written over a horizontal line.

INVESTIGATOR CHOLAKIANS  
#604323

A handwritten signature in black ink, appearing to read "John P. [unclear]", written over a horizontal line.

SUPERVISOR

01/03/2017

---

Date of Report

6

WAS ORIGINAL SCENE DISTURBED BY OTHERS? Y (✓) N ( )  
 IF YES, NOTE CHANGES IN NARRATIVE FORM #3.

DATE 12/27/2016

AMBIENT #1 \_\_\_\_\_ °F NOT TAKEN TIME \_\_\_\_\_

AMBIENT #2 \_\_\_\_\_ °F WITNESSED TIME \_\_\_\_\_

WATER \_\_\_\_\_ °F DEATH TIME \_\_\_\_\_

LIVER TEMPERATURE #1 \_\_\_\_\_ °F TIME \_\_\_\_\_

LIVER TEMPERATURE #2 \_\_\_\_\_ °F TIME \_\_\_\_\_

DATE & TIME FOUND 12/27/2016 0855 HRS LAST KNOWN ALIVE SAME

APPROX. AGE 60 SEX F EST. HEIGHT 61 EST. WEIGHT 171 CLOTHED? YES  NO  IF YES, DESCRIBE:

2016-09419  
 FISHER, CARRIE FRANCES  
 ACC./NAT.  
 12/27/2016  
 THERMOMETER # \_\_\_\_\_

DESCRIPTION AS TO WHERE REMAINS FOUND AND CONTACT MATERIAL TO BODY:

SUPINE ON STEEL TABLE.

SCENE TEMPERATURE REGULATED? YES  NO  IF YES, THERMOSTAT SET AT \_\_\_\_\_ DEGREES F

LIVOR MORTIS: TIME OBSERVED 1255

RIGOR MORTIS TIME OBSERVED 1250

NECK FLEXION. ABSENT

ANTERIOR Ø

POSTERIOR Ø

RT LATERAL Ø

LT LATERAL Ø

JAW Ø

HIP Ø

SHOULDER Ø

KNEE Ø

ELBOW Ø

ANKLE Ø

WRIST Ø

SCALE

0 ABSENT/NEGATIVE

1 .

2 .

3 .

4 EXTREME DEGREE

USE SCALE TO DESCRIBE INTENSITY OF RIGOR MORTIS.

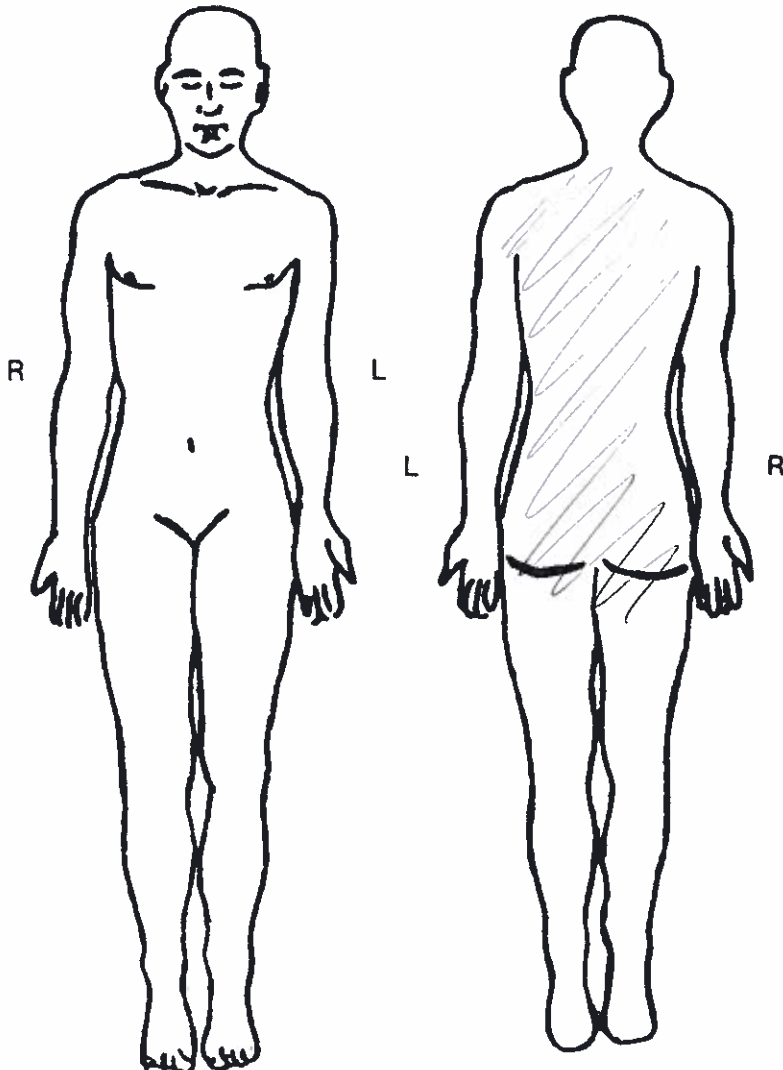
SHADE DIAGRAMS TO ILLUSTRATE THE LOCATION OF LIVOR MORTIS.

DESCRIBE INTENSITY OF COLORATION AND WHETHER LIVOR MORTIS IS PERMANENT OR BLANCHES UNDER PRESSURE

CHOLAKIAN'S #604323  
 CORONER'S INVESTIGATOR

REVIEWED BY

*[Signature]*



Alyssa Fleak

Moleno - death,

COUNTY OF LOS ANGELES  
DEPARTMENT OF MEDICAL EXAMINER-CORONER

HOSPITAL AND NURSING  
CARE FACILITY REPORT

1104 NORTH MISSION ROAD  
LOS ANGELES, CALIF. 90033

18

TO REPORT A DEATH — PHONE (323) 343-0711 FAX (323) 222-7041  
COMPLETE ALL LINES, USE INK. IF UNKNOWN OR NOT APPLICABLE, SO STATE.

CC# 2016-09419.

UCLA Ronald Reagan  
NAME OF FACILITY

FISHER, CARRIE  
FRANCES

ADDRESS 757 Westwood Blvd. HOSPITAL PHONE # \_\_\_\_\_  
NAME OF DECEDENT Carrie Francis Fisher  
SOURCE OF IDENTIFICATION ID - Family DOB 10/21/56 AGE 60 SEX F RACE Caucasian  
DATE OF DEATH 12/27/2016 TIME 0855  
PRONOUNCED BY Sara Stern-Nezer MEDICAL RECORD OR PATIENT FILE # 5210362

**ALL ADMISSION BLOOD SAMPLES/SPECIMENS NEED TO BE HELD FOR  
THE CORONER OR ACCOMPANY DECEDENT/DO NOT DISCARD**

DATE ENTERED HOSPITAL 12/23/2016 TIME 1247 PM 0855 1247 PM  
 SELF  AMBULANCE (Name or R.A.#) RA 51  ER DEATH?  IN PATIENT DEATH?

FROM \_\_\_\_\_ (STATE WHETHER HOME, HOSPITAL OR OTHER) GIVE ADDRESS \_\_\_\_\_ (IF HOSPITAL ATTACH THEIR HISTORY)  
ADMITTED BY: Paul Vespa M.D. PRIMARY ATTENDING PHYSICIAN Kieu, Anh Thuc M.D.  
OFFICE PHONE # 310-206-4100 OFFICE PHONE # \_\_\_\_\_

INJURIES \_\_\_\_\_ DATE \_\_\_\_\_ TIME \_\_\_\_\_ PLACE \_\_\_\_\_ CAUSE \_\_\_\_\_ (TRAFFIC, FALL, ETC.)

DESCRIBE INJURIES:

CLINICAL HISTORY:

SURGICAL PROCEDURES: STATE TYPE, DATE, TIME AND RESULTS OF ANY OPERATION OR AMPUTATION PERFORMED

WAS A BULLET OR OTHER FOREIGN OBJECTS RECOVERED? SPECIFY \_\_\_\_\_

LABORATORY: REPORT ON PATHOLOGY SPECIMENS TAKEN \_\_\_\_\_ DATE & TIME \_\_\_\_\_

LABORATORY PHONE NUMBER \_\_\_\_\_

MICROBIOLOGY CULTURE RESULTS: \_\_\_\_\_ NO \_\_\_\_\_ YES (ATTACH REPORT)

TOXICOLOGY SCREEN: \_\_\_\_\_ NO \_\_\_\_\_ YES (ATTACH RESULTS)

RADIOLOGICAL STUDIES: \_\_\_\_\_ NO \_\_\_\_\_ YES (ATTACH RESULTS)

REMARKS: ESPECIALLY SYMPTOMS PRECEDING AND DURING TERMINAL EPISODE

IN MY OPINION, THE CAUSE OF DEATH IS: \_\_\_\_\_

BY \_\_\_\_\_ M.D. -OR- Deborah Rutkoff

NURSE/HOSPITAL ADMINISTRATOR

OFFICE PHONE # \_\_\_\_\_ OFFICE PHONE # 310-267-6652