

COUNTY OF LOS ANGELES

CASE REPORT

DEPARTMENT OF CORONER

A Nguyen

1

APPARENT MODE ACCIDENT

CASE NO 2013-08211

SPECIAL CIRCUMSTANCES  
Celebrity, Media Interest, Multiple Deaths, Victim of Crime

CRYPT 205

LAST, FIRST MIDDLE

DOE #240, JOHN

AKA

Walker, Fred

# 240

ADDRESS

PLEASE SEE CASE NOTES.

CITY

STATE

ZIP

SEX

RACE

DOB

AGE

HGT

WGT

EYES

HAIR

TEETH

FACIAL HAIR

ID VIEW

CONDITION

MALE

APPEARS CAUCASIAN

09/17/1974

71 in.

173 lbs.

UNKNOW

UNKNOW

ALL NATURAL TEETH

UNKNOW

No

CHARRED

MARK TYPE

MARK LOCATION

MARK DESCRIPTION

NOK

ADDRESS

CITY

STATE

ZIP

PLEASE SEE CASE NOTES.

RELATIONSHIP

PHONE

NOTIFIED BY

DATE

TIME

SSN

DL ID

STATE

PENDING BY

ID METHOD

LA #

MAIN #

CII #

FBI #

MILITARY #

POB

IDENTIFIED BY NAME (PRINT)

RELATIONSHIP

PHONE

DATE

TIME

PLEASE SEE CASE NOTES.

PLACE OF DEATH / PLACE FOUND

ADDRESS OR LOCATION

CITY

ZIP

STREET

HERCULES STREET, WEST OF CONSTITUTION

SANTA CLARITA

91355

PLACE OF INJURY

AT WORK

DATE

TIME

LOCATION OR ADDRESS

ZIP

STREET

No

11/30/2013

15:25

HERCULES STREET, WEST OF CONSTITUTION, SANTA CLARITA, CA

91355

DOD

TIME

FOUND OR PRONOUNCED BY

11/30/2013

15:38

CAPTAIN HITCHCOCK

OTHER AGENCY INV. OFFICER

PHONE

REPORT NO.

NOTIFIED BY

NO

LASD SANTA CLARITA - DEPUTY KELLY

(661) 255-1121

013-16236-0645-470

TRANSPORTED BY

TO

DATE

TIME

ASHLEY JAIME

LOS ANGELES FSC

11/30/2013 22:00

FINGERPRINTS?

No

CLOTHING

Yes

PA RPT

No

MORTUARY

MED. EV.

No

INVEST. PHOTO #

44

SEAL TYPE

NOT SEALED

HOSP RPT

No

PHYS. EV.

No

EVIDENCE LOG

No

PROPERTY?

Yes

HOSP CHART

No

SUICIDE NOTE

No

GSR NO

RCPT. NO.

269436

PF NO.

SYNOPSIS

ACCORDING TO THE REPORTED INFORMATION, THE DECEDENT IS A WHITE MALE, APPROXIMATELY 40 YEARS OLD. ON SATURDAY 11/30/2013 AT APPROXIMATELY 1525 HOURS, THE DECEDENT WAS A PASSENGER IN A PORSCHE CARRERA GT THAT WAS TRAVELLING AT AN UNSAFE SPEED IN THE #1 EASTBOUND LANE ON HERCULES STREET, APPROACHING CONSTITUTION. FOR UNKNOWN REASONS, THE DRIVER LOST CONTROL OF THE VEHICLE, AND THE VEHICLE PARTIALLY SPUN AROUND, AND BEGAN TO TRAVEL IN A SOUTHEAST DIRECTION. THE VEHICLE THEN STRUCK A SIDEWALK AND THE DRIVER'S SIDE OF THE VEHICLE STRUCK A TREE AND THEN A LIGHT POST. THE FORCE OF THOSE COLLISIONS CAUSED THE VEHICLE TO SPIN 180 DEGREES, AND IT CONTINUED TO TRAVEL IN AN EASTERLY DIRECTION. THE PASSENGER SIDE OF THE VEHICLE THEN STRUCK A TREE AND THE VEHICLE BURST INTO FLAMES. 911 WAS CALLED AND DEPUTIES FROM THE LOS ANGELES SHERIFF'S DEPARTMENT-SANTA CLARITA AND FIREFIGHTERS FROM THE LOS ANGELES COUNTY FIRE DEPARTMENT ARRIVED ON-SCENE. ON SATURDAY 11/30/2013 AT 1538 HOURS, CAPTAIN HITCHCOCK FROM ENG156 DETERMINED DEATH. THE DRIVER WAS ALSO DETERMINED DEAD AT THE SCENE, CORONER'S CASE #2013-08210. THERE ARE NO CHARGES PENDING AND THERE ARE NO SIGNS OF FOUL PLAY.

KRISTY MCCRACKEN

491917

[Signature]

INVESTIGATOR

DATE

12/1/2013

TIME

22:55

REVIEWED BY

[Signature]

DATE

12/02/13

TIME

FORM #3 NARRATIVE TO FOLLOW?



County of Los Angeles, Department of Coroner  
Investigator's Narrative



Case Number: 2013-08211

Decedent: DOE #240, JOHN

**Information Sources:**

(1) Los Angeles Sheriff's Department-Santa Clarita (661)255-1121  
Deputy Kelly #404532 Report #013-16236-0645-470

**Investigation:**

On Saturday 11/30/2013 at 1801 hours, Officer Castillo from the Los Angeles Sheriff's Department-Homicide called the Los Angeles County Medical Examiner Coroner's Office to report an accidental death of 2 males, unknown age and race, that were involved in a traffic collision. I assigned this case # to the passenger, and the coroner's case # for the other decedent, the driver, is 2013-08210. On Saturday 11/30/2013 at 1840 hours, I assigned both cases to me. I arrived on-scene at 1950 hours and I cleared the scene at 2145 hours. There are no charges pending and there are no signs of foul play.

**Location:**

The traffic collision occurred and the decedent died on Hercules Street, West of Constitution, Santa Clarita CA, 91355.

**Informant/Witness Statements:**

The following information is preliminary pending further investigation by the handling law enforcement agency.

I spoke with Deputy Kelly at the scene, and he told me the following:

On Saturday 11/30/2013 at approximately 1525 hours, the driver was driving a red Porsche Carrera GT with California license plate #7CCY590 at an unsafe speed, approximately 100+ mph, in the #1 eastbound lane on Hercules Street approaching Constitution. For unknown reasons, the driver lost control of his vehicle, and the vehicle partially spun around, and began traveling in a southeast direction. The vehicle then struck a curb, and the driver's side of the vehicle struck a tree and then a light post. The force of those collisions caused the vehicle to spin 180 degrees and continue in an easterly direction. The passenger side of the vehicle then struck another tree and burst into flames. 911 was called at 1531 hours and Firefighters from the Los Angeles County Fire Department arrived on-scene. On Saturday 11/30/2013 at 1538 hours, Captain Hitchcock from ENG156 determined death for both the driver and the passenger. There are no charges pending.

**Scene Description:**

The traffic collision occurred on Hercules Street, west of Constitution in Santa Clarita. Hercules Street is a major thoroughfare that runs east and west through an industrial area. There are 2 lanes of travel in each direction, and a center lane separating the eastbound lanes from the westbound lanes. The north side was bordered by a bicycle lane, then a sidewalk, and then a brush and tree covered embankment leading up to a parking lot for businesses. The south side was bordered by a bicycle lane, then a brush and tree covered embankment leading down to a parking lot for businesses. Hercules Street had a slight curve west of where the traffic collision occurred with a slight incline. It was dry and well lit with natural sun light at the time of the traffic collision. There were curved skid marks leading from the #1 eastbound lane into the #2 eastbound lane onto the south side embankment. There were multiple miscellaneous pieces of vehicle debris across all 4 lanes and into the parking lot on the south side of Hercules Street.

Located on the top of the south side embankment was sheared off cement light pole. Located south of the central portion of the downed light pole was a broken tree. Located a few feet east of the end of the sheared light pole was the red Porsche Carrera GT with California license plate #7CCY590. The vehicle was located on all 4 of its wheels with the front of the vehicle facing



County of Los Angeles, Department of Coroner  
Investigator's Narrative



Case Number: 2013-08211

Decedent: DOE #240, JOHN

east and the rear of the vehicle facing south. Part of the passenger side was resting against another broken tree. The vehicle was totaled with major traffic collision damage all around, and it appeared that the vehicle was almost split in half. The majority of the vehicle was also charred. The decedent was located lying supine in the passenger seat.

**Evidence:**

I did not collect any evidence regarding this case.

**Body Examination:**

The decedent is a white male, approximately 40 years old with an unknown hair color and length, unknown eye color, and it is unknown if he had any facial hair. He has all of his upper and lower natural teeth. No scars or tattoos were noted. The decedent was wearing remnants of a black T-shirt, a pair of black jeans, and a pair of gray boxer briefs. The decedent was located lying supine in the passenger seat. The top of his head was facing west. His right arm was bent at the elbow with his right hand in the air, parallel with the central portion of his torso. His left arm was bent at the elbow with his left hand on the ground, just above the other decedent's head. Both of his legs were bent at the knees with both of his feet resting on the passenger floorboard. I was unable to see which direction they were pointing. The decedent was charred and in a pugilistic stance. His right wrist was fractured and his left arm was fractured. Rigor mortis and lividity were not observed.

**Identification:**

The decedent cannot be positively identified visually. The decedent is probably Paul William Walker IV with a DOB of 09/12/1973. Please see case notes for further information

**Next of Kin Notification:**

On Saturday 11/30/2013 at an unknown time, [REDACTED] the decedent's father and [REDACTED], the decedent's mother, were tentatively notified of their son's death. When I spoke with [REDACTED] over the phone, they both confirmed this information.


**Tissue Donation:**


Due to the extent of the injuries, the decedent is not viable candidate for tissue donation.

**Exam Notification:**

There are no exam notifications regarding this case.

  
KRISTY MCCRACKEN #491917

  
SUPERVISOR

  
Date of Report

6

WAS ORIGINAL SCENE DISTURBED BY OTHERS? Y( ) N(X)

IF YES, NOTE CHANGES IN NARRATIVE FORM #3.

DATE 11/30/13  
AMBIENT #1 \_\_\_\_\_ °F TIME \_\_\_\_\_  
AMBIENT #2 \_\_\_\_\_ °F TIME \_\_\_\_\_  
WATER \_\_\_\_\_ °F TIME \_\_\_\_\_

2013-08211  
DOE #240,  
JOHN  
ACC-T/C  
THERMOMETER # \_\_\_\_\_

LIVER TEMPERATURE #1 \_\_\_\_\_ °F TIME \_\_\_\_\_

LIVER TEMPERATURE #2 \_\_\_\_\_ °F TIME \_\_\_\_\_

DATE & TIME FOUND 11/30/13 1525 LAST KNOWN ALIVE 11/30/13 1525

APPROX. AGE 40 SEX M EST. HEIGHT 71 EST. WEIGHT 173 CLOTHED? YES(X) NO( ) IF YES, DESCRIBE:  
1-T-shirt, 1-Jeans, 1-Boxer Briefs

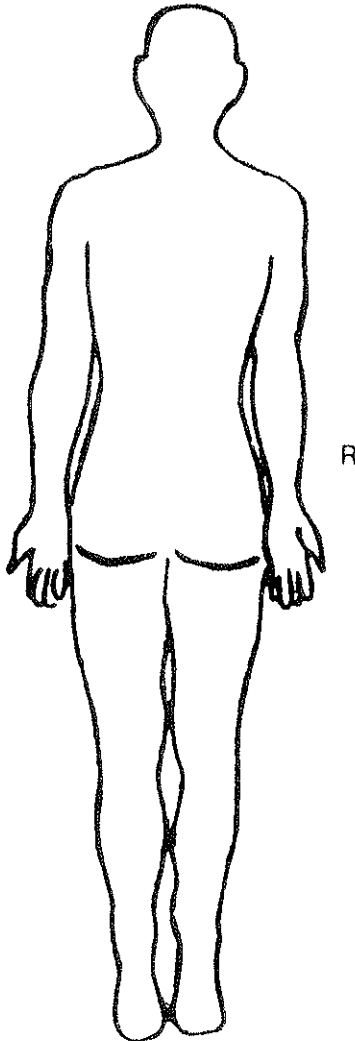
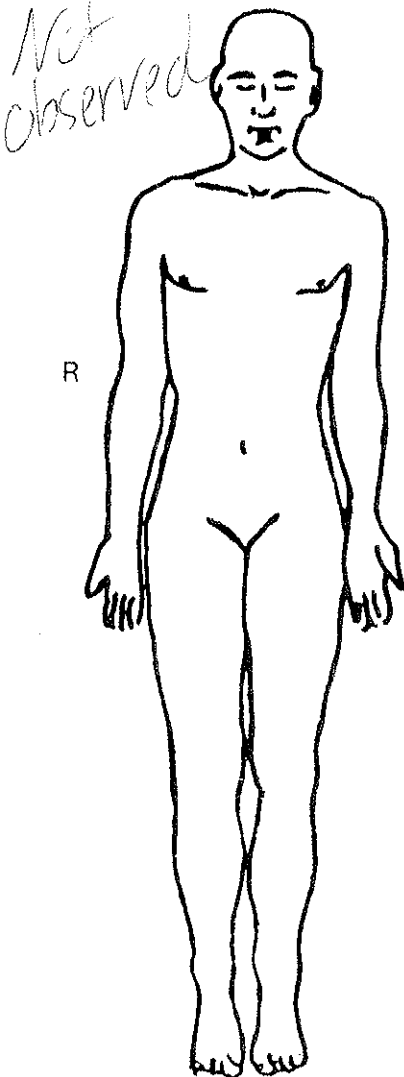
DESCRIPTION AS TO WHERE REMAINS FOUND AND CONTACT MATERIAL TO BODY

Lying supine in the passenger seat

SCENE TEMPERATURE REGULATED? YES( ) NO(X) IF YES, THERMOSTAT SET AT \_\_\_\_\_ DEGREES F

LIVOR MORTIS TIME OBSERVED Unk

RIGOR MORTIS TIME OBSERVED Unk



NECK FLEXION

ANTERIOR N/A  
POSTERIOR N/A  
RT LATERAL N/A  
LT LATERAL N/A

JAW N/A  
SHOULDER N/A  
ELBOW N/A  
WRIST N/A  
HIP N/A  
KNEE N/A  
ANKLE N/A

- SCALE
- 0 ABSENT/NEGATIVE
  - 1 .
  - 2 .
  - 3 .
  - 4 EXTREME DEGREE

USE SCALE TO DESCRIBE INTENSITY OF RIGOR MORTIS

SHADE DIAGRAMS TO ILLUSTRATE THE LOCATION OF LIVOR MORTIS

DESCRIBE INTENSITY OF COLORATION AND WHETHER LIVOR MORTIS IS PERMANENT OR BLANCHES UNDER PRESSURE.

K. McCracken #491917  
CORONER'S INVESTIGATOR

REVIEWED BY

Handwritten signature

**12****AUTOPSY REPORT**

No.

2013-08211

WALKER IV, PAUL WILLIAM

I performed an autopsy on the body of  at \_\_\_\_\_  
the DEPARTMENT OF CORONER

Los Angeles, California

on DECEMBER 3, 2013 @ 0800 HOURS  
(Date) (Time)

From the anatomic findings and pertinent history I ascribe the death to:

(A) **COMBINED EFFECTS OF TRAUMATIC AND THERMAL INJURIES**

DUE TO, OR AS A CONSEQUENCE OF

(B)

DUE TO, OR AS A CONSEQUENCE OF

(C)

DUE TO, OR AS A CONSEQUENCE OF

(D)

OTHER CONDITIONS CONTRIBUTING BUT NOT RELATED TO THE IMMEDIATE CAUSE OF DEATH:

*Anatomical Summary:*

## I. Extensive thermal injuries.

- A. Diffuse charring of the skin with sparing of the back, buttocks, and feet.
- B. Fractures of the right distal radius and ulna, likely heat related.
- C. Epidural clotting, right-sided.
- D. Scant soot present within the trachea.

## II. Multiple traumatic injuries.

- A. Left mandible fracture.
- B. Left clavicle fracture.
- C. Left humerus fracture.
- D. Multiple rib fractures.
- E. Multiple pelvic fractures.
- F. Nondisplaced spinal fracture at the level of T6.

**12****AUTOPSY REPORT**

No.

2013-08211

WALKER IV, PAUL WILLIAM

Page 2

## CIRCUMSTANCES:

See Investigator's Report Form #3.

## EXTERNAL DESCRIPTION:

The body is identified by toe tags and is that of an adult male. The body weighs 173 pounds, measures 71 inches and is well-built, muscular and fairly well-nourished. The body shows extensive thermal burns with diffuse charring. The upper extremities show pugilistic-type posturing with fractures of the distal radius and ulna that appear to be heat-related. The fractured ends show charring due to thermal injuries. There is exposure of the skull and exposure of muscle on the torso and extremities.

The head is normocephalic. Most of the hair is burned and hair color cannot be determined. Examination of the eyes reveals clouded corneas. Eye color cannot be determined. The oronasal passages are unobstructed. There is tongue protrusion from the mouth. Upper and lower teeth are present. The neck is straight and without hypermobility. There is no chest deformity. The abdomen is flat. The genitalia are those of an adult male. Examination of the back reveals skin spared of charring at the lower back and buttocks. There is also sparing of charring of both feet.

## TRAUMATIC INJURIES:

1. Left mandible fracture.
2. Left clavicle fracture.
3. Left humerus fracture.
4. Multiple rib fractures:
  - a. Left anterior lateral ribs 3 through 6; right posterior lateral ribs 3 through 5; right lateral ribs 9-10.
5. Multiple pelvic fractures, more prominent on the right side.
6. Nondisplaced spinal fracture at the level of T6, with a faint focal  $\frac{1}{4}$  inch spinal cord contusion. There is surrounding prevetebral hemorrhage.

**12****AUTOPSY REPORT**

No.

2013-08211

WALKER IV, PAUL WILLIAM

Page 3

## NECK:

The neck organs are removed en bloc with the tongue. There is no edema of the larynx. Both hyoid bone and larynx are intact and without fractures. No hemorrhage is present in the adjacent throat organs, investing fascia, strap muscles, thyroid or visceral fascia. There are no cervical prevertebral fascial hemorrhages. The cervical spine is examined by palpation and reveals no fractures or dislocations. The tongue when sectioned shows no trauma. The trachea is opened longitudinally and reveals scant soot present and a mild amount of frothy fluid.

## CHEST/ABDOMINAL CAVITY:

Both pleural cavities contain no fluid or adhesions. The lungs are well-expanded. The subcutaneous fat of the abdominal wall measures 1.5 cm. The organs of the abdominal cavity have a normal arrangement and none are absent. There is no fluid collection. The peritoneal cavity is without evidence of peritonitis.

SYSTEMIC AND ORGAN REVIEW

## CARDIOVASCULAR SYSTEM:

The aorta is elastic and of even caliber throughout with vessels distributed normally from it. The thoracic and abdominal aorta are without atherosclerosis. There is no tortuosity or widening of the thoracic segment. There is no dilation of the lower abdominal segment. No aneurysm is present. Within the pericardial sac there is a minimal amount of serous fluid. The heart weighs 425 grams and has a normal configuration. The right ventricle is 0.3 cm thick and the left ventricle is 1.3 cm thick. The intraventricular septum is 1.3 cm thick. The chambers are normally developed and are without mural thrombosis. The valves are thin, leafy and competent. There is no endocardial discoloration. There are no lesions of the myocardium. There is no abnormality of the apices of the papillary musculature. There are no defects of the septum. The great vessels enter and leave in a normal fashion. The coronary ostia are patent. There is a normal pattern of coronary artery distribution. There is

**12****AUTOPSY REPORT**

No.

2013-08211

WALKER IV, PAUL WILLIAM

Page 4

no atherosclerosis of the major coronary arteries. No focal endocardial valvular or myocardial lesions are seen. The blood within the heart and large blood vessels is liquid.

**RESPIRATORY SYSTEM:**

Mild bloody fluid is found in the upper bronchial passages. The mucosa appears unremarkable. The lungs are subcrepitant. The right lung weighs 850 grams. The left lung weighs 1000 grams. The visceral pleura are smooth and intact. The parenchyma shows bilateral pulmonary hemorrhage diffusely. The pulmonary vasculature is without thromboembolism.

**GASTROINTESTINAL SYSTEM:**

The esophagus is intact throughout. The stomach is not distended. It contains 30 cc of brown gastric material. The mucosa is unremarkable. Portions of tablets and capsules cannot be discerned in the stomach. The small intestine and colon are opened along the anti-mesenteric border and are unremarkable. The appendix is present. The pancreas occupies a normal position and is unremarkable.

**HEPATOBIILIARY SYSTEM:**

The liver weighs 1675 grams, is of average size and is red-brown. The capsule is intact and the consistency of the parenchyma is soft. The cut surface is smooth. There is a normal lobular arrangement. The gallbladder is present. The wall is thin and pliable. It contains 5 cc of bile and no calculi.

**URINARY SYSTEM:**

The left kidney weighs 175 grams. The right kidney weighs 175 grams. The kidneys are normally situated and the capsules strip easily revealing surfaces that are smooth. The corticomedullary demarcation is preserved. The urinary bladder is unremarkable. It contains 150 cc of blood tinged urine.



**12****AUTOPSY REPORT**

No.

2013-08211

WALKER IV, PAUL WILLIAM

Page 5

## GENITAL SYSTEM:

The prostate is without enlargement or nodularity.

## HEMOLYMPHATIC SYSTEM:

The spleen weighs 200 grams and is of average size. The capsule is intact. The parenchyma is dark-red. There is no increased follicular pattern. The lymph nodes throughout the body are small and inconspicuous. The bone density is not remarkable. The bone marrow of the rib and vertebra are unremarkable.

## ENDOCRINE SYSTEM:

The thyroid is unremarkable. The parathyroid glands are not identified. The adrenals are unremarkable. The pituitary gland is unremarkable.

## HEAD AND CENTRAL NERVOUS SYSTEM:

There is no subcutaneous or subgaleal hemorrhages in the scalp. The external periosteum and dura mater are stripped showing no acute fractures of the calvarium or base of the skull. There are no tears of the dura mater. There is caked, right-sided, epidural clotting. The clotting is maroon-colored and estimated to be 15 cc in quantity. In the region of the clotting, focal charring is seen on the inner table of the calvarium at the right temporal parietal junction.

The brain weighs 1525 grams. The leptomeninges are thin and transparent. A flattened convolutionary pattern is observed. Coronal sectioning demonstrates a uniformity of cortical gray thickness. The cerebral hemispheres are symmetrical. There is no softening, discoloration, or hemorrhage of the white matter. The basal ganglia are intact. Anatomic landmarks are preserved. Cerebral contusions are not present. The ventricular system is unremarkable without dilation or distortion. Pons, medulla and cerebellum are unremarkable. There is no evidence of uncal or cerebellar herniation. Vessels at the base of the brain have a normal pattern of distribution. There are no aneurysms. The cerebral arteries are without arteriosclerosis.

**12****AUTOPSY REPORT**

No.

2013-08211

WALKER IV, PAUL WILLIAM

Page 6

## SPINAL CORD:

The entire cord is dissected revealing a faint focal contusion of the level of T6 as previously described.

## HISTOLOGIC SECTIONS:

Representative sections from various organs are preserved in one storage jar in 10% formalin.

## TOXICOLOGY:

Blood, liver tissue, stomach contents, urine and vitreous humor have been submitted to the lab. A traffic screen was requested.

## PHOTOGRAPHY:

Photographs have been taken prior to the autopsy.

## RADIOLOGY:

Multiple x-rays are obtained.

## WITNESSES:

None.

## DIAGRAMS USED:

Diagram Form #20 was used in the performance of the autopsy. The diagram is not intended to be a facsimile.

**12****AUTOPSY REPORT**

No.


2013-08211

WALKER IV, PAUL WILLIAM

Page 7

## OPINION:

The cause of death is combined effects of traumatic and thermal injuries. The manner of death is accident.



LAWRENCE NGUYEN, M.D.  
DEPUTY MEDICAL EXAMINER

12/31/13

DATE

LN:sa/c

D:12/03/13

T:12/24/13

15

AUTOPSY CLASS:  A  B  C  Examination Only D

FAMILY OBJECTION TO AUTOPSY

Date: 12/3/13 Time: 0800 Dr. Nguyen (Print)

FINAL ON: 12/3/13 By: Nguyen (Print)

APPROXIMATE INTERVAL BETWEEN ONSET AND DEATH

2013-08211  
JUN 9 00E 240

2013

DEATH WAS CAUSED BY: (Enter only one cause per line for A, B, C, and D)

IMMEDIATE CAUSE:

(A) Combined effects of traumatic and thermal injuries

Rapid

Age: \_\_\_\_\_ Gender: (Male) / Female

DUE TO, OR AS A CONSEQUENCE OF:

(B)

PRIOR EXAMINATION REVIEW BY DME

- BODY TAG  CLOTHING
- X-RAY (No. A)  FLUORO
- SPECIAL PROCESSING TAG  MED. RECORDS
- AT SCENE PHOTOS (No. \_\_\_\_\_)

DUE TO, OR AS A CONSEQUENCE OF:

(C)

CASE CIRCUMSTANCES

- EMBALMED
- DECOMPOSED
- >24 HRS IN HOSPITAL
- OTHER: \_\_\_\_\_ (Reason)

DUE TO, OR AS A CONSEQUENCE OF:

(D)

OTHER CONDITIONS CONTRIBUTING BUT NOT RELATED TO THE IMMEDIATE CAUSE OF DEATH:

TYPING SPECIMEN

TYPING SPECIMEN TAKEN BY: NGUYEN  
SOURCE: HEART X 2

- NATURAL  SUICIDE  HOMICIDE
- ACCIDENT  COULD NOT BE DETERMINED

TOXICOLOGY SPECIMEN

- COLLECTED BY: NGUYEN
- HEART BLOOD  STOMACH CONTENTS
  - FEMORAL BLOOD  VITREOUS
- TECHNIQUE: internal
- \_\_\_\_\_ BLOOD  SPLEEN
  - \_\_\_\_\_ BLOOD  KIDNEY
  - BILE  \_\_\_\_\_
  - LIVER  \_\_\_\_\_
  - URINE  \_\_\_\_\_

If other than natural causes, HOW DID INJURY OCCUR? Auto (passenger) vs. fixed object

URINE GLUCOSE DIPSTICK RESULT: 4+ 3+ 2+ 1+ 0

TOX SPECIMEN RECONCILIATION BY: A

WAS OPERATION PERFORMED FOR ANY CONDITION STATED ABOVE:  YES  NO

TYPE OF SURGERY: \_\_\_\_\_ DATE: \_\_\_\_\_

- ORGAN PROCUREMENT  TECHNICIAN: white
- PREGNANCY IN LAST YEAR  YES  NO  UNK  NOT APPLICABLE
- WITNESS TO AUTOPSY  EVIDENCE RECOVERED AT AUTOPSY

HISTOLOGY

- Regular (No. 1)  Oversize (No. \_\_\_\_\_)
- Histopath Cut:  Autopsy  Lab

TOXICOLOGY REQUESTS

- FORM 3A:  YES  NO
- NO TOXICOLOGY REQUESTED
  - SCREEN  C  H  T  S  D
  - ALCOHOL ONLY
  - CARBON MONOXIDE
  - OTHER (Specify drug and tissue)

REQUESTED MATERIAL ON PENDING CASES

- POLICE REPORT  MED HISTORY
- TOX FOR COD  HISTOLOGY
- TOX FOR R/O  INVESTIGATIONS
- MICROBIOLOGY  EYE PATH. CONS.
- RADIOLOGY CONS.
- CONSULT ON: \_\_\_\_\_
- BRAIN SUBMITTED
- NEURO CONSULT  DME TO CUT
- CRIMINALISTICS
- GSR  SEXUAL ASSAULT  OTHER

RESIDENT

DME

James Z. Nguyen

16

2013-08211  
JAN DOE 240

205

EXTERNAL EXAM

Sex M  
Race  
Age  
Height 71  
Weight 173  
Hair unk  
Eyes unk  
Sclera  
Teeth present  
Mouth  
Tongue protrusion  
Nose  
Chest  
Breasts  
Abdomen  
Scar  
Genital ♂  
Edema  
Skin extensive thermal injuries  
Decub

HEART Wt. 425

Pericard  
Hypert  
Dilat  
Muscle } unremarkable  
Valves }  
Coronar ♂ CAD

RV 0.3  
LV 1.3  
Septum 1.3

AORTA unremarkable

VESSELS

LUNGS Wt

R 850  
L 1000  
Adhes none  
Fluid  
Atelectasis  
Oedema  
Congest pulmonary hemorrhage, bilat  
Consol  
Bronchi bloody  
Nodes

PHARYNX

TRACHEA scant snot present; mild frothy fluid

THYROID nL

THYMUS

LARYNX unremarkable

HYOID unremarkable

ABDOMINAL WALL FAT 1.5 cm

PERITONEUM

Fluid none  
Adhes none

LIVER Wt 1675

Caps  
Lobul } unremarkable  
Fibros - none  
G B ⊕  
Calc none  
Bile ducts

SPLEEN Wt 200

Color  
Consist } unremarkable  
Caps  
Malpig

PANCREAS unremarkable

ADRENALS unremarkable

KIDNEYS Wt

R 175  
L 175  
Caps  
Cortex  
Vessels } unremarkable  
Pelvis  
Ureter

BLADDER 150 cc blood tinged

GENITALIA

Prost unremarkable  
Testes  
Uterus  
Tubes  
Ovar

OESOPHAGUS unremarkable

STOMACH

Contents 30 cc brown

DUOD & SM INT unremarkable

APPENDIX ⊕

LARGE INT unremarkable

ABDOM NODES

SKELETON

Spine fracture T6  
Marrow  
Rib Cage frx (R) L 3-4; (R) L 7-8; (L) L 9-10  
Long bones # distal radius/ulna (charred ends)  
Pelvis fractures and # numerous  
Mandible fracture (left)  
Left clavicle fracture

SCALP charred

CALVARIUM charring seen on right inner calvarium/parietal

BRAIN Wt 1525

Edema  
Dura  
Fluid } unremarkable  
Ventric  
Vessels  
Middle ears  
Other ⊕ epidural clotting

PITUITARY ⊕

SPINAL CORD

spinal contusion at T6 level

TOXICOLOGY SPECIMENS

blood, liver, urine, sc, vit

SECTIONS FOR HISTOPATHOLOGY

(1) storage jar

MICROBIOLOGY

DIAGRAMS #20

X-RAYS (19)

OTHER PROCEDURES

GROSS IMPRESSIONS

multiple thermal and traumatic injuries

Date

Time

Deputy Medical Examiner

12/3/13

0800

*Lawrence E. Myer*

20

2013-08211  
JAN 09 247

205

"pygistic" type posturing  
extensive thermal burns  
with diffuse charring  
of the body  
exposure of skull  
exposure of muscle  
on the torso and  
extremities

fracture of  
left mandible

fracture of  
humerus

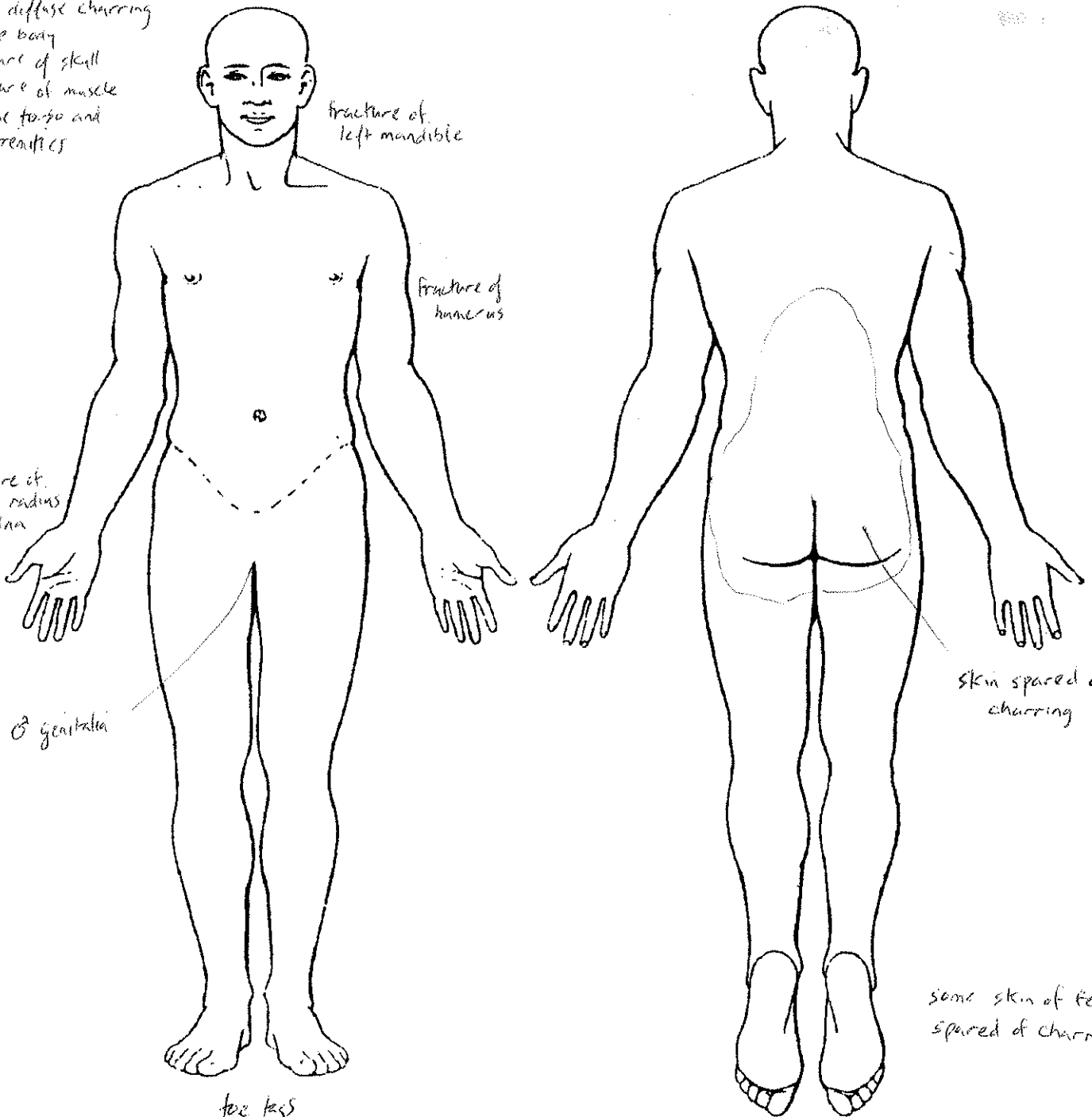
fracture of  
distal radius  
and ulna

♂ genitalia

toe tags

skin spared of  
charring

some skin of feet  
spared of charring



Date 12/3/17

*James L. Nguyen*

Deputy Medical Examiner

M.D.



Department of Medical Examiner-Coroner, County of Los Angeles

**FORENSIC SCIENCE LABORATORIES**

1104 North Mission Road Los Angeles, CA 90033

**Laboratory Analysis Summary Report**



Nguyen, Lawrence M.D.

Deputy Medical Examiner  
1104 North Mission Road  
Los Angeles, CA 90033

PendingTox

The following results have been technically and administratively reviewed and are the opinions and conclusions of the Analyst:

**Coroner Case Number:** 2013-08211 **Decedent:** WALKER IV, PAUL WILLIAM

<u>SPECIMEN</u>	<u>SERVICE</u>	<u>DRUG</u>	<u>RESULT</u>	<u>ANALYST</u>
Blood, Heart				
	Alcohol-GC/FID-HS	Ethanol	Negative	M. Schuchardt
	ELISA-Immunoassay	Cocaine and Metabolites	ND	T. Montero
	ELISA-Immunoassay	Marijuana: 11-nor-Delta-9-Carboxy-THC	ND	T. Montero
	ELISA-Immunoassay	Methamphetamine & MDMA	ND	T. Montero
	ELISA-Immunoassay	Opiates: Codeine & Morphine	ND	T. Montero
	ELISA-Immunoassay	Opiates: Hydrocodone & Hydromorphone	ND	T. Montero

**EDTA Blood**

Carbon Monoxide-CO-Ox    Carboxyhemoglobin    14 % Saturation    O. Pleitez

NOTE; The source of the EDTA Blood is from the Heart.

<b>Legend:</b>		mg/dL	Milligram per Deciliter	QNS	Quantity Not Sufficient
g	Grams	mg/L	Milligram per Liter	TNP	Test Not Performed
g%	Gram Percent	ND	Not Detected	ug	Micrograms
Inc.	Inconclusive	ng/g	Nanograms per Gram	ug/g	Micrograms per Gram
mg	Milligrams	ng/mL	Nanograms per Milliliter	ug/mL	Microgram per Milliliter

In accordance with the Department's Evidence Retention Policy, the blood specimen(s) will be retained for one-year and all other specimens for six-months from Autopsy.

Administratively reviewed by:

**Daniel T. Anderson,** M.S., FTS-ABFT, D-ABC  
**Supervising Criminalist II**  
**TOXICOLOGY**

(323) 343-0660 DAnderson@coroner.lacounty.gov